

# The prevalence and distribution of gastric ulceration in 345 racehorses

LM BEGG and CB O'SULLIVAN

Randwick Equine Centre, 3 Jane Street, Randwick, New South Wales 2031

**Objective** To report the prevalence and distribution of gastric ulceration within a group of racehorses and to describe the endoscopic appearance of gastric antrum and pyloric ulceration.

**Design** Retrospective clinical study.

**Procedure** Medical records from gastroscopic examinations of 345 racehorses (331 Thoroughbreds and 14 Standardbreds) were reviewed. Prevalence, distribution and severity of gastric ulcers were recorded. Lesions involving the squamous mucosa and the glandular mucosa of the antrum and pylorus were graded and compared.

**Results** Gastric ulceration was found in 86% of racehorses. The squamous mucosa around the margo plicatus was most commonly affected. The pylorus was examined in 175 horses and 47% were ulcerated. No association was found between presence of lesions of the squamous mucosa and those of the pylorus. Low correlation was found between grade and location of lesions, with the pyloric lesion score being significantly less than the squamous mucosal lesion score.

**Conclusion** Gastric ulceration was present in a large proportion of racehorses. The pylorus was also an important site of ulceration. There was no association between presence of lesion at one site and the other, although there was a low correlation between grade of lesion and location, with the pyloric ulcer grade being lower.

*Aust Vet J* 2003;81:199-201

The prevalence of gastric ulceration in Thoroughbred racehorses is reported to be between 66 and 93%.<sup>1-3</sup> The prevalence is known to increase to 80 to 100% as duration in training increases and horses commence racing.<sup>1,2</sup> Ulceration has been reported to involve most commonly the squamous portion of the gastric mucosa adjacent to the margo plicatus.<sup>4,5</sup> Although the procedure for endoscopic examination of the antrum and pylorus was first described in 1985,<sup>6</sup> no information on prevalence of ulceration in this area occurred in the literature until recently. In a recent study of 162 horses in the United States, it was shown that 58% of horses had ulceration of this site.<sup>7</sup>

The purpose of the current study was to report the prevalence and distribution of gastric ulceration in a group of racehorses trained under Australian conditions and to describe the endoscopic findings involving the gastric antrum and pylorus.

## Materials and methods

Medical records were reviewed from 345 racehorses (331 Thoroughbreds and 14 Standardbreds) that had gastroscopic examinations performed by either of the authors between 1997 and 2001. There were 185 geldings, 35 colts and 125 fillies, ranging in age from 1 to 8 years, with a mean age of 3.3 years.

Only horses in race training with no previous diagnosis or treatment for gastric ulceration were included. Most were exam-

ined due to the clinical signs of inappetence, poor condition or poor performance. Others were examined as part of a survey within one stable. Food was withheld for 12 hours and sedation was provided with xylazine at 0.4 to 0.8 mg/kg. Endoscopic examinations were performed using a 3 m videoendoscope (EV-P2900L, Pentax). The stomach was insufflated with air until the mucosal lining of the stomach was smooth. Gastric contents were removed from the mucosa by flushing water through the endoscope biopsy channel. The margo plicatus was viewed along the greater and lesser curvatures of the stomach. The fundus was visualised, then the endoscope tip was passed down into the gastric fluid and remaining ingesta until the antrum and pylorus were viewed. Some horses that had not been adequately starved had solid feed material in the stomach, preventing the pylorus from being visualised. The latter part of the examination was sometimes protracted due to inability to control accurately the direction and placement of the endoscope in the stomach. In these horses examination of the pylorus was not completed due to lack of patient compliance, or due to time constraints on use of the facilities. All horses in which the pylorus was not examined were excluded from the comparison between lesion location and severity.

Gastric lesions were characterised by location and assigned a severity score of 0 to III, based on ulcer depth and surface area. Superficial erosion was considered grade I, superficial erosion with some areas of submucosa exposed was considered grade II, and if all the mucosa was eroded the lesion was considered grade III (Figure 1 and 2). If greater than 50% of the surface area of the region was involved, the grade was increased by one. The location of ulceration was determined by dividing the stomach into five anatomical regions. The squamous mucosa 5 cm proximal to the margo plicatus was divided into two regions, the greater and lesser curvatures. The remaining area of squamous mucosa dorsally was considered the fundus. The glandular mucosa was considered to be that area visible above the fluid line. The antrum and pylorus were graded together. In comparisons of lesion presence and severity between squamous and pyloric mucosa, the squamous mucosa score used was the more severe of the greater and lesser curvature scores. Most horses were examined with both authors present.

A chi squared test was used to compare frequency of occurrence of lesions of the squamous mucosa with the frequency of occurrence of lesions of the pyloric mucosa. A Spearman Rank Order Correlation was then used to compare grade of lesion between the two sites. To determine if there was a significant difference between scores at each site a Mann-Whitney Rank Sum Test was used.

## Results

Of the 345 horses, 296 (86%) had ulceration of the squamous mucosa, with the squamous mucosa around the margo plicatus the most commonly affected site. The greater curvature was most affected in 25% of horses, the lesser curvature was

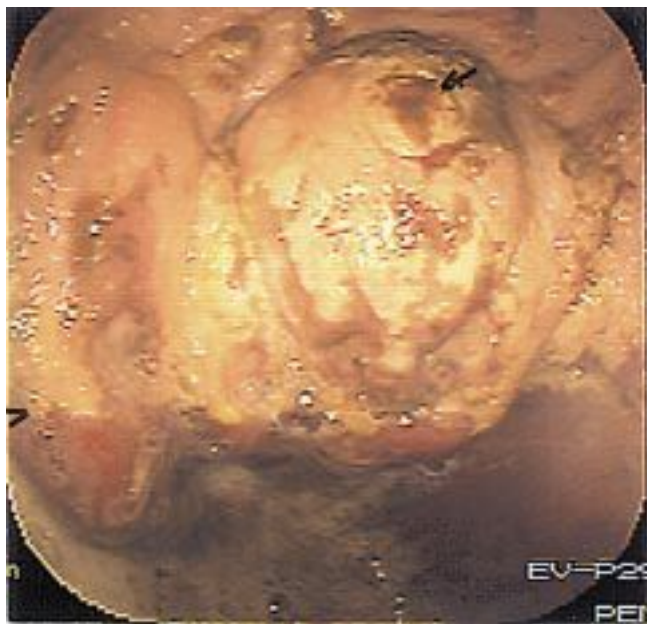

Figure 1. Image from a videoendoscopic examination of a horse's stomach showing grade III lesions (arrow) in the squamous mucosa above the margo plicatus (arrow head) on the greater curvature.

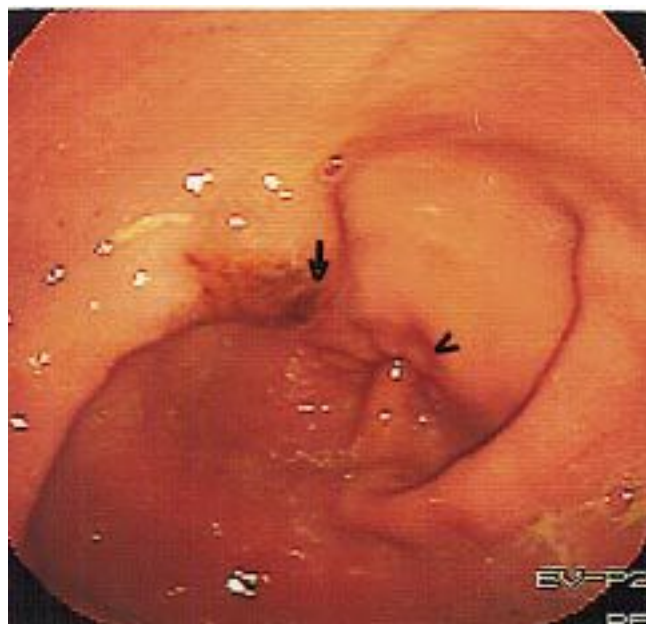


Figure 2. Image from a videoendoscopic examination of a horse's stomach showing a grade III lesion (arrow) in the glandular mucosa adjacent to the pylorus (arrow head).

most affected in 26% of horses and both were equally affected in 49% of horses. The pylorus was examined in 175 horses and 83 (47%) were found to have ulcers at this site (Table I).

The frequency of occurrence of lesions was different between the squamous and pyloric mucosa ( $P < 0.05$ ). There was a significant ( $P < 0.001$ ) although low correlation ( $r_s = 0.28$ ) between ulcer severity and its location: the lesion severity score of pyloric mucosa was found to be significantly lower (median score 0; 25 and 75% percentiles 0 and I) than of the squamous mucosa (median score II; 25 and 75% percentiles I and III;  $P < 0.001$ ).

## Discussion

Gastric ulceration was present in a large proportion (86%) of horses examined, and this is consistent with previous reports of between 66 and 93% of Thoroughbred racehorses in training being affected.<sup>1,2</sup> This group of horses, as with previous studies, was not randomly sampled and may only approximate the true prevalence of disease in the population.<sup>1,3,4</sup> The anatomical distribution of ulceration was similar between greater and lesser curvatures of the stomach, with squamous mucosa around the margo plicatus being most commonly affected, as has previously been reported.<sup>4,5</sup> In this study, we found that 47% of pylori viewed were ulcerated, which is less than the 58% found in a previous report.<sup>7</sup> In our study however, only racehorses in work were included.

The frequency of occurrence of lesions was found to be significantly different ( $P < 0.05$ ) between squamous and pyloric mucosa, and this is in agreement with previous findings.<sup>7</sup> When a lesion did exist however, we found a significant, although low, correlation between grade and location, with the pyloric mucosal grade being significantly lower than the squamous mucosal grade. This is in contrast to a previous study, which found no correlation between grade and location of lesions for these two sites.<sup>7</sup> This finding is interesting, as the pathogenesis

Table I. Lesion scores (number of horses with each score) for the gastric squamous and pyloric mucosa for 175 horses in which both regions were examined.

		Pyloric mucosa			
		0	I	II	III
		(92)	(54)	(19)	(10)
Squamous Mucosa					
0	(12)	12	0	0	0
I	(37)	26	5	6	0
II	(53)	25	19	8	1
III	(73)	29	30	5	9

of gastric ulceration is presently unknown. The most common theory is that ulceration occurs as a result of prolonged exposure to hydrochloric acid with intermittent feeding practices, which is particularly damaging to the squamous mucosal lining of the stomach, an area with minimal protective factors.<sup>8</sup> The glandular mucosa, on the other hand, has a protective mucous-bicarbonate layer that prevents acid injury.<sup>8</sup> Other protective factors are thought to be prostaglandin E<sub>2</sub>, mucosal blood flow, cellular restitution and, probably, epidermal growth factor.<sup>8</sup> The effect of gastric pH as the inciting cause of ulceration would explain the lower grade in the pyloric mucosa.

*Helicobacter pylori* infects the glandular mucosa in man and plays a role in the pathogenesis of gastric ulceration.<sup>9</sup> To date, this bacterium has not been identified in equine gastric mucosa, however, if present in the horse, *Helicobacter* would be expected to cause more severe ulceration in the glandular mucosa, as it does not colonise alimentary squamous epithelium.<sup>9</sup> Another

possible pathogenesis for pyloric ulceration is reflux of bile acids back into the stomach from the duodenum.<sup>7</sup> If this was the case, however, the severity of pyloric ulceration would be expected to be greater than that of the squamous mucosa, as the pylorus would be exposed to greater concentrations of bile acids.

The finding that there was no association between the severity of squamous mucosal ulceration and that of the pyloric mucosa emphasises the importance of examining the antrum and pylorus when performing gastroscopy on racehorses. There was a relatively high occurrence of ulceration at the pylorus and its presence could not be inferred by the appearance of the squamous mucosa.

### Acknowledgments

We thank Dr David Evans for his assistance with the statistical analysis.

### References

1. Hammond CJ, Mason DK, Watkins KL. Gastric ulceration in mature thoroughbred horses. *Equine Vet J* 1986;18:284-287.
2. Murray MJ, Schusser GF, Pipers FS, Gross SJ. Factors associated with gastric lesions in thoroughbred racehorses. *Equine Vet J* 1996;28:368-374.
3. Murray MJ. Gastric ulceration in horses: 91 cases (1987-1990). *J Am Vet Med Assoc* 1992;201:117-120.
4. Vatistas NJ, Snyder JR, Carlson G et al. Cross-sectional study of gastric ulcers of the squamous mucosa in thoroughbred racehorses. *Equine Vet J* 1999 Suppl. 29:34-39.
5. Furr MO, Murray MJ. Treatment of gastric ulcers in horses with histamine type 2 receptor antagonists. *Equine Vet J* 1989 Suppl. 7:77-79.
6. Brown CM, Slocumbe RF, Derksen FJ. Fiberoptic gastroduodenoscopy in the horse. *J Am Vet Med Assoc* 1985;186:965-968.
7. Murray MJ, Nout YS, Ward DL. Endoscopic findings of the gastric antrum and pylorus in horses: 162 cases (1996-2000) *J Vet Intern Med* 2001;15:401-406.
8. Murray MJ. Gastroduodenal ulceration. In: Reed SM, Bayley WM, editors. *Equine Internal Medicine*. Saunders, Philadelphia, 1998:615-623.
9. Murray MJ. Gastroduodenal ulceration. In: Robinson NE, editor. *Current Therapy in Equine Medicine*. 4th edn. Saunders, Philadelphia, 1997:191-197.

(Accepted for publication 11 December 2002)

## CLINICAL CORRESPONDENCE

### Unusual foreign body on the tongue of a dog

D McMILLAN  
G MALLETT

Cairns Veterinary Clinic,  
76 Pease Street,  
Cairns, Queensland 4870

A female Rottweiler cross was presented at 0700 h with a massively swollen tongue. The tongue was engorged with blood, extruded and several times normal size. The oropharynx was occluded, preventing complete examination in the conscious dog. No foreign body was initially apparent. Differential diagnoses included a lingual foreign body, abscessation, or an inflammatory process such as a bite or sting.

Dexamethasone sodium phosphate (10 mg) and 250 mg of frusemide were administered intravenously, and 50 mg of chlorpheniramine maleate was injected subcutaneously.

Needle aspiration from several sites on the tongue produced scant dark blood.

The dog was sedated with 6 mg acepromazine and 1 mg atropine. We induced a light plane of anaesthesia using intravenous thiopentone to effect. Examination of the oropharynx

revealed a 7 mm strip of pale material encircling the base of the tongue. The dog was intubated and maintained on oxygen. The foreign body was removed. It comprised a round section of great vessel and attached auricle. The internal diameter was 25 mm, and the width of the band 10 mm.

The tongue was manually 'milked' to reduce its size, with slight improvement.

The dog was maintained on intravenous fluids, and offered water, but was unable to lap. The tongue was lubricated with cooking oil aerosol to prevent dehydration.

The dog was discharged with a guarded prognosis for tongue survival. The owners were instructed to offer water in a large vessel, and syringe water into the throat if the dog remained unable to lap.

The dog's tongue remained protruded and dysfunctional. Three days later part of the tongue sloughed away. The dog died later that day. An autopsy was not performed.

This is an unusual case of lingual foreign body. Many owners feed ovine or bovine heart to their dogs, and it would be difficult for a dog to push its tongue through a vascular ring in this way. The dog may have attempted to lick inside the heart chambers, and torn the vessel away after the tongue became engorged. A possible means of prevention would be to slice the heart to open all vessels longitudinally.